REVIEW ARTICLE

Mucormycosis

Dimitrios P. Kontoyiannis, M.D., Sc.D.,[1] and Thomas J. Walsh, M.D.[2-4]

SUMMARY

Mucormycosis is a rapidly progressive, invasive fungal infection that affects patients who are severely immunocompromised, as well as patients with diabetes and persons with immunocompetence who have major trauma. Mucormycosis manifests in several clinical forms, including sino-orbital, rhinocerebral, sinopulmonary, gastrointestinal, cutaneous, musculoskeletal, osteoarticular, and disseminated mucormycosis, as well as single-organ disease. Although mucormycosis is often lethal, early intervention reduces mortality. Successful treatment depends on early detection and staging of the disease, timely initiation of antifungal therapy, surgical resection of infected tissue, reversal of immunodeficiencies, and correction of metabolic abnormalities. Liposomal amphotericin B is the preferred agent for initial antifungal therapy, with oral triazoles as alternative agents. Research on rapid molecular diagnostic strategies, new antifungal agents, host-directed immune augmentation, antivirulence immune therapeutics, and risk-based stratification to inform management of disease may substantially improve outcomes in patients with this highly destructive mycosis.

Author affiliations are listed at the end of the article. Dimitrios P. Kontoyiannis can be contacted at dkontoyi@mdanderson.org or at the Division of Internal Medicine, Department of Infectious Diseases, Infection Control, and Employee Health, University of Texas M.D. Anderson Cancer Center, 1515 Holcombe Blvd., Unit 1460, Houston, TX 77030. Thomas J. Walsh can be contacted at tjwalsh@citdx.org.

N Engl J Med 2026;394:684-98.
DOI: 10.1056/NEJMra2412565
Copyright © 2026 Massachusetts Medical Society.

CME

Mucormycosis (formerly known as zygomycosis)[1] is a rapidly progressive and frequently lethal invasive fungal disease of the lungs, sinuses, orbits, and brain in immunocompromised hosts, including patients with hematologic cancers, a history of transplantation, or diabetes.[2] Among patients with immunocompetence, mucormycosis is increasingly recognized as a cause of serious necrotizing infections of traumatic wounds.[3] Recently discovered risk factors include coronavirus disease 2019 (Covid-19), chimeric antigen receptor T-cell therapy, and use of ibrutinib.[4-7] Mucormycosis manifests in several well-described clinical forms, including sino-orbital, rhinocerebral, sinopulmonary, gastrointestinal, cutaneous, musculoskeletal, osteoarticular, and disseminated mucormycosis, as well as single-organ disease.[2] The World Health Organization has designated the mucorales as high-priority pathogens, a reflection of the increasing global importance of mucormycosis.[8] Essential for successful management of mucormycosis is a multidisciplinary clinical team that consists of infectious-disease physicians, internists, pediatricians, surgeons, intensivists, hematologists, transplantation specialists, ophthalmologists, clinical microbiologists, anatomical pathologists, and diagnostic and interventional radiologists.

Among the invasive mycoses, mucormycosis is widely considered to be the most rapidly invasive and destructive. Members of the order Mucorales have angioinvasive characteristics — related to secreted proteases, a ricinlike toxin, and affinity for endothelial cells — that result in tissue infarction.[9,10] India has been recognized as an area of hyperendemicity for mucormycosis, and this status is thought to be attributable in part to a combination of geoclimatic factors and a high prevalence of

The New England Journal of Medicine is produced by NEJM Group, a division of the Massachusetts Medical Society.
Downloaded from nejm.org by TOM HSIUNG on February 27, 2026.
Copyright © 2026 Massachusetts Medical Society. All rights reserved, including those for text and data mining, AI training, and similar technologies.

diabetes. The estimated disease burden in India is approximately 70 times higher than the global average, with more than 200,000 cases per year predicted in India.[11] As climate change contributes to greater frequency and severity of some natural disasters, an increase in cases of mucormycosis may occur.[12]

MYCOLOGIC FEATURES

The term "mucormycosis" encompasses a severe, often fatal constellation of invasive fungal diseases, first described in 1885 as mycosis mucorina, which are caused by members of the order Mucorales within the subphylum Mucormycotina.[1] Mucormycosis was previously known as zygomycosis because the causative agents belonged to the phylum Zygomycota (class Zygomycetes). However, after advances in molecular phylogenetics showed that Zygomycota was polyphyletic, the classification was revised, with the updated taxa including the class Mucormycetes and the medically important order Mucorales. As a consequence, the term "zygomycosis" was replaced by "mucormycosis." The most commonly encountered and medically important genera are rhizopus, mucor, lichtheimia, cunninghamella, apophysomyces, and saksenaea. Several studies have shown *Cunninghamella bertholletiae* to have greater virulence than other mucormycetes and to be associated with higher mortality.[13,14]

Mucorales species are found ubiquitously in soil and decaying organic matter. The environmental form of mucorales species when they are growing in nature consists of a mycelium (a mat of hyphae) that produces sporangiospores 3 to 11 μm in diameter. These sporangiospores are inhaled into the respiratory tract, in which pulmonary alveolar macrophages (a component of innate host defenses) are efficient at eliminating them by phagocytosis.

However, in patients who are severely immunocompromised, some sporangiospores are not cleared and instead adhere to and invade respiratory epithelial cells by means of CotH surface proteins.[15] The hyphal forms that emerge from germinated sporangiospores are broad, ribbonlike, angioinvasive structures that cross tissue planes, which results in ischemia, necrosis, and hematogenous dissemination.

Mucorales species have been identified historically by phenotypic methods that assess the arrangement of sporangia, sporangiophores, and rhizoids (if present), as well as the characteristics of the sporangiospores. Broad, nonseptate (coenocytic) or sparsely septate (pauciseptate) hyphae in tissue with angioinvasion are also characteristic of mucormycosis. However, misidentification of mucormycosis on the basis of histopathological features alone may occur. In situ molecular probes, direct sequencing, and immunohistochemical and metagenomic analyses are molecular diagnostic tools that can identify mucorales species.[16]

HOST DEFENSES AND PATHOGENESIS

The complex and robust innate immune response to the sporangiospores of mucorales species prevents development of mucormycosis in persons with immunocompetence.[17] The mucociliary clearance mechanisms of pseudostratified columnar respiratory epithelial cells are mechanical barriers that remove sporangiospores. Invasion of alveolar epithelial cells by mucorales fungi induces transcriptional activation of epithelial proinflammatory cytokines, chemokines, and adhesion molecules (Fig. 1A). Pulmonary alveolar macrophages provide another line of innate host defenses by means of phagocytosis and destruction of sporangiospores in phagolysosomes. Intracellular swelling of sporangiospores (a critical step in pathogenesis) is further inhibited by iron deprivation.[18]

Neutrophils are the first-line innate host defense against mucorales hyphae (Fig. 1B) through reactive oxygen species and nonoxidative mechanisms, including actions of cationic antimicrobial peptides.[19] Recognition of hyphae by pattern recognition receptors such as toll-like receptor 2 activates neutrophils and induces the release of proinflammatory cytokines. Interferon-γ, granulocyte–macrophage colony-stimulating factor (GM-CSF), tumor necrosis factor α, and interleukin-8 further augment neutrophil function in response to hyphae.

In patients who are immunocompromised, mucormycosis develops as the result of quantitative or qualitative defects in phagocytic activity caused by neutropenia and functional defects in macrophages, neutrophils, and lymphocytes, including natural killer cells. Glucocorticoids impair

The New England Journal of Medicine is produced by NEJM Group, a division of the Massachusetts Medical Society.
Downloaded from nejm.org by TOM HSIUNG on February 27, 2026.
Copyright © 2026 Massachusetts Medical Society. All rights reserved, including those for text and data mining, AI training, and similar technologies.

A Modes of Mucorales Infection

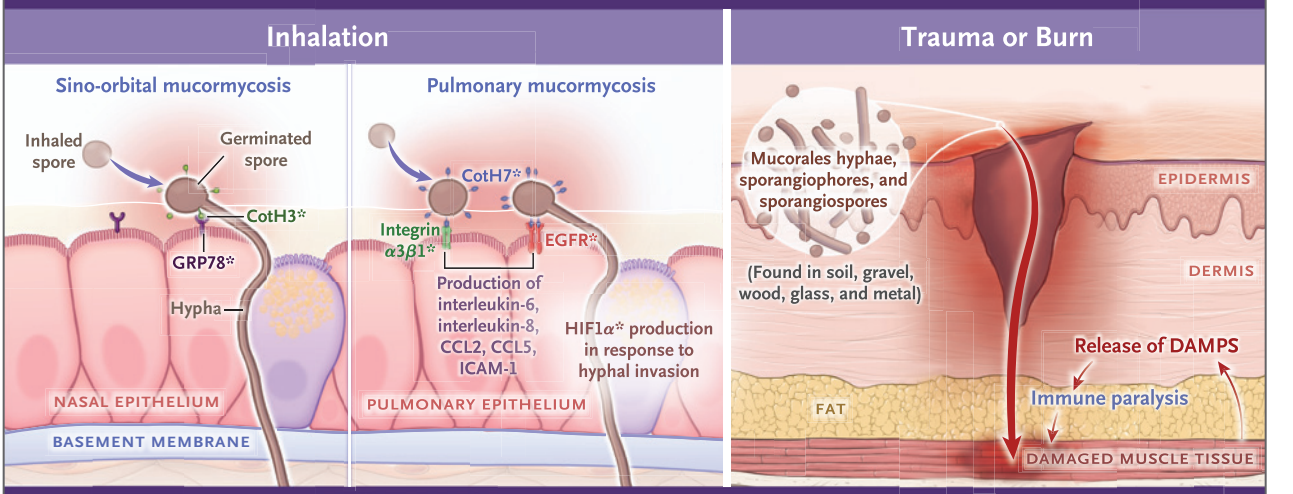

B Endovascular Pathogenesis

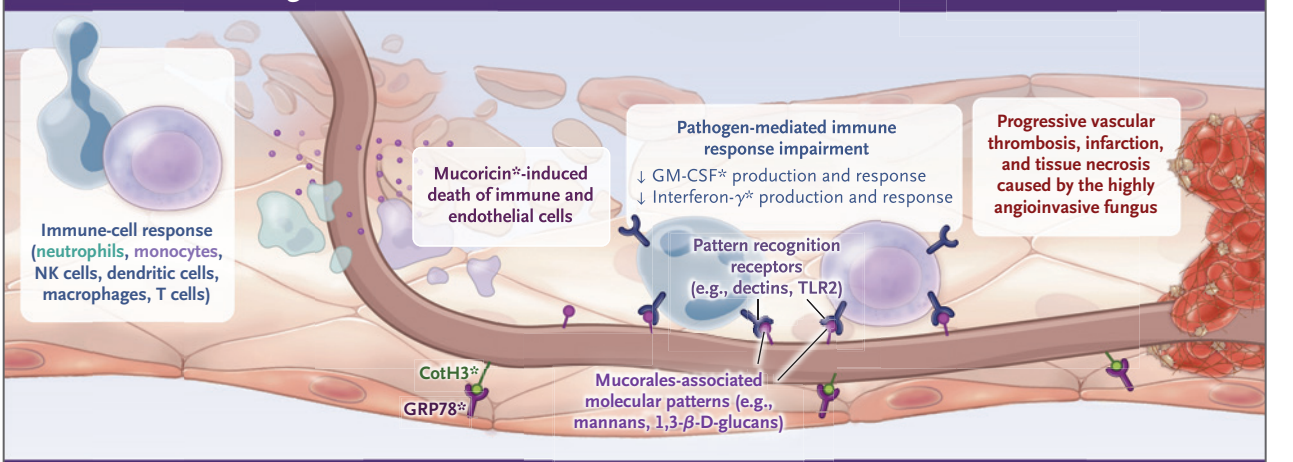

C Factors in the Tissue Microenvironment That Promote Mucorales Invasion

High glucose levels and low pH levels (diabetic acidosis, treatment of Covid-19 with glucocorticoids, other metabolic disorders with acidemia)	• Increased CotH3* expression on mucorales spores • Increased GRP78* expression on host endothelial cells • Increased available free iron* – Increased growth of mucorales
Immunometabolic factors (low serum albumin or malnutrition)	• Increased unbound oxidized fatty acids • Decreased serum antifungal activity • Increased mucoricin* and adhesin expression by mucorales
Neutropenia, monocytopenia, or use of glucocorticoids	• Impaired phagocytosis of mucorales and subsequent dissemination of pathogen • Functional impairment of neutrophils, macrophages, and monocytes • Cytokine deficiencies (GM-CSF*, interferon-γ*) • Immune-cell exhaustion mediated by checkpoint molecules such as PD-1* and PDL-1*
Iron-overload conditions	• Increased available free iron* – Increased growth of mucorales
Severe trauma or burns	• Release of DAMPs • Immune paralysis – Proteolysis of immune receptors – Defective regulation of lysosomal pH – Impaired chemotaxis – Decreased Th17 cells

The New England Journal of Medicine is produced by NEJM Group, a division of the Massachusetts Medical Society.
Downloaded from nejm.org by TOM HSIUNG on February 27, 2026.
Copyright © 2026 Massachusetts Medical Society. All rights reserved, including those for text and data mining, AI training, and similar technologies.

Figure 1 (facing page). Pathogenesis of Mucormycosis, Host Defenses, and Potential Future Therapeutic Targets.

Mucorales sporangiospores released into the air from sporangia are inhaled, and the sporangiospore coat protein CotH3 binds to glucose-regulated protein 78 (GRP78) on the pseudostratified columnar epithelial cells of the upper respiratory tract, where the sporangiospores may germinate into hyphae to invade nasal airways and sinuses (Panel A). Sporangiospores, by means of another coat adhesin (CotH7), also bind to epidermal growth factor receptor (EGFR) and integrin $\alpha 3\beta 1$ receptor on pulmonary alveolar epithelial cells of the lower respiratory tract, which triggers a downstream transcriptional response involving cytokines (interleukin-6 and interleukin-8), chemokines (CCL2 and CCL5), and intercellular adhesion molecule 1 (ICAM-1). Hyphal invasion also triggers production of hypoxia-inducible factor 1α (HIF1α) and release of proinflammatory cytokines. In wound-related mucormycosis, traumatic inoculation of fungal elements (found on the surfaces of rocks, wood, glass, and metal) into damaged tissue allows for the development of infection in a host with immune paralysis due to trauma. The release of endogenous host-derived molecules known as damage-associated molecular patterns (DAMPs) reduces phagocytosis, impairs chemotaxis, and induces immune paralysis. Mucoricin released by the invading hyphae induces death of immune and endothelial cells, which results in tissue necrosis and accelerates endovascular thrombosis, ischemia, and infarction (Panel B). Polymorphonuclear neutrophils and monocytes recognize early germinated sporangiospores by means of pattern recognition receptors (e.g., toll-like receptor 2 [TLR2]) that detect mucorales-associated molecular patterns (e.g., 1,3-β-D-glucans exposed on hyphal structures). Intrinsic host colony-stimulating factors such as granulocyte–macrophage colony-stimulating factor (GM-CSF) and interferon-γ further contribute to augmentation of innate host defenses against the invading hyphae, which in turn dampen immune responses. Factors in the tissue microenvironment that increase susceptibility to mucorales invasion are listed with the predominant mechanisms associated (Panel C). Asterisks indicate potential future therapeutic targets. Covid-19 denotes coronavirus disease 2019, NK natural killer, PD-1 programmed cell death protein 1, PD-L1 programmed death ligand 1, Th1 type 1 helper T, Th2 type 2 helper T, and Th17 type 17 helper T.

both neutrophil and macrophage host responses against mucorales species. Hyperglycemia and metabolic acidosis in patients with diabetes permit proliferation of hyphae and impair phagocytic oxidative and nonoxidative host responses. Hypoalbuminemia also contributes to progression of mucormycosis; free fatty acids bound to albumin restrict mucorales growth, but hypoalbuminemia allows oxidation of unbound free fatty acids and increases the expression of mucorales virulence genes.[20]

Angioinvasion, thrombosis, and tissue infarction are pathophysiological and clinical hallmarks of mucormycosis. The CotH spore coat proteins of rhizopus differentially bind to host receptors glucose-regulated protein 78 (GRP78) on nasal epithelial cells and integrin $\alpha 3\beta 1$ on alveolar epithelial cells.[19,21] The CotH3 protein of invading hyphae binds to the endothelial receptor GRP78, a process that allows for angioinvasion and thrombosis. Mucoricin, a 17-kD ricin-like toxin, also contributes to cellular injury and tissue necrosis.[10] CotH3 and GRP78 are up-regulated by metabolic acidosis as a pivotal event in the angioinvasive pathogenesis of rhinocerebral mucormycosis (Fig. 1A). In children with inherited disorders of metabolism, such as methylmalonic aciduria, metabolic acidosis alone is sufficient to induce mucormycosis. Metabolic acidosis in patients with poorly controlled type 1 diabetes may be the basis for a higher risk of mucormycosis among patients with type 1 diabetes than among those with type 2 diabetes. Glycemic and acidemic control in patients with diabetes reduces the risk of mucormycosis.

Iron metabolism also has a key role in the pathogenesis of mucormycosis and in host defenses in patients with diabetes.[18,19] Mucorales species are dependent on the acquisition of free ionic iron from infected hosts. Metabolic acidosis decreases the affinity of transferrin and ferritin for iron, which results in the availability of more free iron. Increased glycosylation of transferrin and ferritin that results from poorly controlled diabetes also increases the availability of free iron. The effect of excess available iron was observed in patients with disseminated mucormycosis who received deferoxamine for hemochromatosis and other iron-overload conditions.[19]

In patients with blast injuries, burns, and other major trauma who were previously healthy, mucormycosis may develop in the context of "immune paralysis" (Fig. 1A). Investigation of the mechanisms of immune paralysis in such patients showed that functional neutropenia occurs when mediators released from the damaged tissue create a tissue microenvironment that causes local neutrophil dysfunction and immune dysregulation (Fig. 1C).[3,22]

The New England Journal of Medicine is produced by NEJM Group, a division of the Massachusetts Medical Society.
Downloaded from nejm.org by TOM HSIUNG on February 27, 2026.
Copyright © 2026 Massachusetts Medical Society. All rights reserved, including those for text and data mining, AI training, and similar technologies.

Table 1. Risk Factors for Mucormycosis and Clinical Manifestations of Disease.*

Clinical Form	Common Risk Factors	Symptoms	Clinical Features and Findings on Diagnostic Imaging	Comments
Sino-orbital[26,27]	Diabetes† Hematologic cancers Hematopoietic-cell transplantation Solid-organ transplantation Severe aplastic anemia Covid-19‡ Prolonged use of high-dose glucocorticoids	Congestion Localized sinus pain Odontogenic pain in cases of maxillary-sinus infection Nasal discharge Headache	Infection of nasal turbinates: ulcerations, eschars Maxillary-sinus infection: palatal ischemia or necrosis and involvement of the molars and premolars Ethmoid-sinus infection: hyposmia or anosmia; extension through the lamina papyracea bone into the orbit with entrapment of the medial rectus muscle and other extraocular muscles and progression to orbital apex syndrome	Sphenoidal mucormycosis may manifest with referred pain in the vertex of the skull. Sino-orbital mucormycosis is a medical and surgical emergency. Early examination and reexamination with imaging and otolaryngologic evaluation are important.
Rhinocerebral[26,27]	Diabetes† Hematologic cancers Hematopoietic-cell transplantation Solid-organ transplantation Severe aplastic anemia Covid-19‡ Prolonged use of high-dose glucocorticoids	Diplopia related to cranial nerve deficits Seizures	Focal neurologic deficits Extension from ethmoid sinuses and frontal sinuses into veins draining into the cavernous sinus, with damage to cranial nerves III, IV, V1, V2, and VI and the internal carotid artery	Frontal sinus mucormycosis may be complicated by direct extension into frontal lobes, which is indicated by meningeal enhancement of tissue invasion. Rhinocerebral mucormycosis is a medical and surgical emergency. Early examination and reexamination with imaging and otolaryngologic evaluation are important.
Sinopulmonary[28-31]§	Hematopoietic-cell transplantation Solid-organ transplantation Severe aplastic anemia Covid-19‡ Prolonged use of high-dose glucocorticoids	Cough Dyspnea Pleuritic pain	Persistent fever refractory to empirical antibacterial therapy Hemoptysis Multiple pulmonary nodules with the halo sign or reversed halo sign on CT scan Intrathoracic extension of disease into the pleura, ribs, diaphragm, mediastinum, and pericardium	Angioinvasive properties lead to necrotizing pneumonia with pulmonary infarction and hemorrhage. Tracheobronchitis, bronchial obstruction, severe or fatal hemoptysis, and cavitary fungus ball are rare manifestations. The presence of a reversed halo sign is more highly suggestive of pulmonary mucormycosis than the conventional halo sign, which is associated with pulmonary aspergillosis and infection with other angioinvasive molds in patients with hematologic cancer.
Cutaneous and musculoskeletal[3,32-34]	Trauma Burns Blast injuries Severe natural disasters (e.g., tornadoes, tsunamis, floods, earthquakes) Premature birth Immunosuppression	Local pain at the site of injury	Cutaneous ulcerations Brown-black eschars with firm, woody consistency and deep necrotizing extension into fascia, tendon, and muscle	This form occurs in infants who are born prematurely and exposed to contaminated bed linens; it also occurs in patients who are immunocompromised, especially during neutropenia, as the result of cutaneous inoculation from soil or plant sources. CT scans, MRI, and surgical exploration typically show that the degree of subcutaneous infection is much deeper and more extensive than what can be detected on physical examination. The differential diagnosis includes cutaneous aspergillosis, fusariosis, and ecthyma gangrenosum caused by *Pseudomonas aeruginosa* and other gram-negative bacilli.

The New England Journal of Medicine is produced by NEJM Group, a division of the Massachusetts Medical Society.
Downloaded from nejm.org by TOM HSIUNG on February 27, 2026.
Copyright © 2026 Massachusetts Medical Society. All rights reserved, including those for text and data mining, AI training, and similar technologies.

Osteoarticular[33]	Severe trauma Blast injuries Intravenous drug use Immunosuppression	Local pain at the site of injury Tenderness Erythema Limited range of motion	Tenderness with overlying cellulitis Lytic bone destruction at the site of direct or hematogenous inoculation	Infection of bone and joints may occur as a result of direct traumatic inoculation after severe trauma, blast injuries, or intravenous drug use. Osteoarticular mucormycosis also occurs in patients who are immunocompromised by means of direct extension from infected foci or hematogenous dissemination. In view of the broad differential diagnosis, which includes cancer and several other infectious entities, bone biopsy and cultures are indicated.
Gastrointestinal[35-37]	Premature birth Severe malnutrition Immunosuppression Pica	Abdominal pain Nausea Vomiting Hematemesis Abdominal tenderness Hematochezia Melena Abdominal distension	Gastrointestinal hemorrhage, obstruction, perforation, or infarction Intraabdominal dissemination	Gastrointestinal mucormycosis should be distinguished from gastrointestinal basidiobolomycosis.¶ Patients who are immunocompromised may become infected after ingesting contaminated food or herbal medicinal products containing mucorales species. This form is commonly diagnosed post mortem.
Disseminated[38]	Hematologic cancers Hematopoietic-cell transplantation Solid-organ transplantation Severe aplastic anemia Endocarditis (may be associated with illicit drug use)	Focal seizures	Focal neurologic deficits arising from involvement of the central nervous system	Involvement of the central nervous system is common. Other affected sites (alone or in combination with other organs) may include the lungs, spleen, kidneys, and thyroid. Dissemination most commonly arises from the lung but may also arise from a cutaneous lesion.
Early manifestations	High pretest probability that mucormycosis will develop	Diplopia	Periorbital cellulitis Focal palatal necrosis Necrotic wounds (consistent with angioinvasion)	These early sentinel clinical manifestations call for urgent assessment.

* CT denotes computed tomography.
† Sino-orbital mucormycosis and rhinocerebral mucormycosis are the most common manifestations in patients with diabetes, especially those with type 1 diabetes or poorly controlled diabetes with ketoacidosis.
‡ Sino-orbital mucormycosis and rhinocerebral mucormycosis are the most common manifestations of coronavirus disease 2019 (Covid-19)–associated mucormycosis.
§ In addition to the lungs, any single organ may also be infected through either cryptic hematogenous dissemination or traumatic inoculation.
¶ Basidiobolomycosis is an indolent, chronic granulomatous fungal disease that causes constriction and obstruction of the intestinal tract; treatment, which is usually triazole-based, has been successful with itraconazole.

The New England Journal of Medicine is produced by NEJM Group, a division of the Massachusetts Medical Society.
Downloaded from nejm.org by TOM HSIUNG on February 27, 2026.
Copyright © 2026 Massachusetts Medical Society. All rights reserved, including those for text and data mining, AI training, and similar technologies.

EPIDEMIOLOGIC FEATURES AND RISK FACTORS

Because mucormycosis is not a reportable disease, the exact incidence or prevalence is unknown. An older population-based study of mucormycosis in San Francisco showed an estimated incidence of 1.7 cases per 1 million population.[23] However, other studies have shown regional differences and an increase in the incidence over time.[5,11,24] Moreover, retrospective data from January 2005 through June 2014 show a substantial clinical and economic burden from mucormycosis-related hospitalizations in the United States, with a prevalence of 0.12 per 10,000 discharges, high costs (an average of $112,419 per stay), long stays (median, 17 days), and high in-hospital mortality (23%).[24] Important risk factors for mucormycosis include diabetes, hematologic cancers, allogeneic hematopoietic-cell transplantation, severe graft-versus-host disease, solid-organ transplantation, prolonged use of high-dose glucocorticoids, low birth weight, metabolic acidosis, iron-overload states, injection-drug use, and severe malnutrition (Table 1).[2,25-42]

Several reports from India indicated an increase in the incidence of Covid-19–associated mucormycosis in late 2020 and early 2021, and the incidence reached a peak of more than 51,000 cases in 2021.[4,5] Covid-19–associated mucormycosis typically manifests as sino-orbital and rhinocerebral disease in patients with poorly controlled diabetes with hyperglycemia, ketoacidosis, and an elevated glycated hemoglobin level. Covid-19–associated mucormycosis may reflect the deleterious convergence of critical host and environmental factors, including poorly controlled diabetes, use of glucocorticoids to control the pulmonary inflammatory response to severe acute respiratory syndrome coronavirus 2, and possibly Covid-19–induced dysimmunoregulation.[42]

Nosocomial and home environmental sources of mucorales species also increase the risk of mucormycosis.[34,43] Contaminated air-handling systems, arm boards used with intravenous tubing, plants, and hospital construction have been implicated as sources of nosocomial mucormycosis, as have bed linens contaminated with sporangiospores.[34] Linens have also been considered to be the source of cutaneous mucormycosis in low-birth-weight infants in neonatal intensive care units.

In patients who are immunocompromised, gastrointestinal mucormycosis develops after ingestion of sporangiospores in herbal remedies, homeopathic medicines, food, and substances consumed in the context of pica.[35,36] Gastrointestinal mucormycosis also occurs in low-birth-weight infants[37] and is associated with high mortality — close to 100% — in this population as a result of gastrointestinal perforation and intraabdominal dissemination.

The profile of infection differs between neonates and older children.[37] Whereas older children with persistent neutropenia, a history of transplantation, rare metabolic disorders, or type 1 diabetes are at risk for sino-orbital, rhinocerebral, and pulmonary mucormycosis, infants have a significantly greater risk of cutaneous or gastrointestinal mucormycosis than older children, and mortality associated with mucormycosis is significantly higher among infants.

CLINICAL MANIFESTATIONS

The clinical manifestations of mucormycosis include sino-orbital, rhinocerebral, sinopulmonary, cutaneous, musculoskeletal, gastrointestinal, osteoarticular, disseminated, and single-organ disease and are driven by angioinvasive and infarctive properties (Table 1).[26-42] The various forms of mucormycosis appear to have a predilection for hosts with specific characteristics. Sino-orbital and rhinocerebral disease are the most common manifestations in patients with diabetes, whereas sinopulmonary and disseminated mucormycosis are more common in patients with severe immunosuppression. In addition, some mucorales species have a predilection toward specific clinical manifestations; for example, *Apophysomyces elegans* and *Saksenaea vasiformis* are common causes of mucormycosis in the context of combat-wound and storm-associated cutaneous and musculoskeletal trauma.[3,12,13,32,33]

DIAGNOSIS

Early diagnosis and initiation of antifungal therapy significantly reduce mortality among patients with mucormycosis and hematologic cancers,

The New England Journal of Medicine is produced by NEJM Group, a division of the Massachusetts Medical Society.
Downloaded from nejm.org by TOM HSIUNG on February 27, 2026.
Copyright © 2026 Massachusetts Medical Society. All rights reserved, including those for text and data mining, AI training, and similar technologies.

from approximately 80% to 40%.[44] Accurate diagnosis of mucormycosis begins at the bedside with evaluation of symptoms and signs in patients at high risk (Table 1 and Fig. 2). Although early symptoms and physical findings in patients with mucormycosis are often nonspecific, they carry important diagnostic significance in patient populations with high risk.[26-33,38]

Periorbital cellulitis, diplopia, focal palatal necrosis, and necrotic wounds in patients at high risk should cause serious concern for mucormycosis and lead to prompt assessment (Fig. 2). Maintaining a high index of suspicion for mucormycosis in such patients can be the impetus for obtaining fluids and tissues for diagnostic analysis, ordering imaging procedures, initiating antifungal therapy, requesting surgical assessment, reversing immunodeficiencies, and correcting metabolic abnormalities.

The staging of mucormycosis, which has critical implications for treatment and outcomes, depends on a comprehensive examination, diagnostic imaging, and laboratory-confirmed diagnosis (Table 2). For suspected sino-orbital disease, staging includes diagnostic imaging (computed tomography [CT]) of the paranasal sinuses and chest, as well as endoscopic examination of nasal turbinates with brush biopsy of ulcerations and necrotic eschars (Table 1). In sino-orbital or sinus mucormycosis, CT and magnetic resonance imaging (MRI) scans of the sinuses or head may be unremarkable during early phases of disease, which underscores the need for close monitoring by physical examination, repeat imaging, and follow-up endoscopy.[26,27] For patients in whom pulmonary lesions are suspected, bronchoalveolar lavage, preferably with biopsy, should be per-

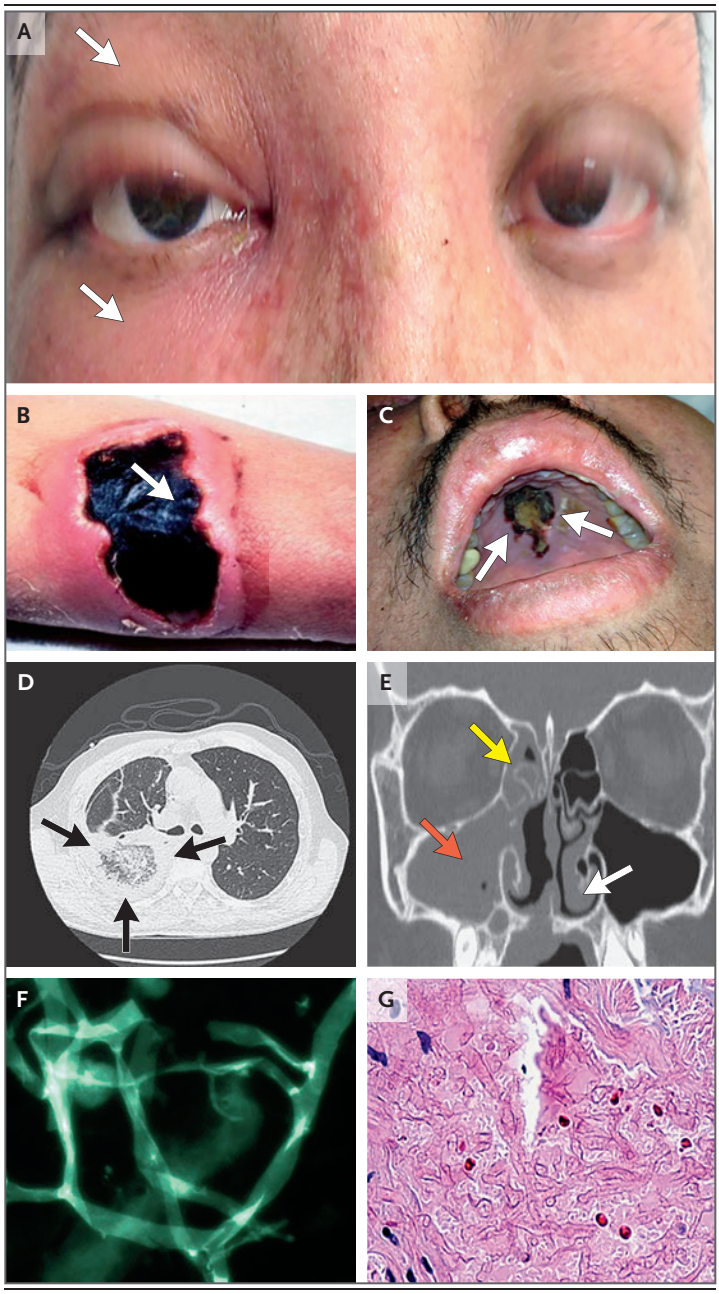

Figure 2. Direct Examination and CT Imaging in Mucormycosis.

Sino-orbital mucormycosis is associated with right periorbital cellulitis (Panel A, arrows) and ophthalmoplegia. Cutaneous mucormycosis is characterized by blackened, raised eschars (Panel B, arrow). Lesions due to palatal mucormycosis are shown (Panel C, arrows). In pulmonary mucormycosis, a large reversed halo sign (Panel D, arrows) in the right lower lobe is characterized by a pulmonary infiltrate with a central ground-glass opacity that is circumscribed by denser air-space opacities. (Photo used with permission from Dr. Genovefa Papanicolaou.) Examples of imaging results in mucormycosis of the right maxillary sinus (Panel E, red arrow), right ethmoid sinus (yellow arrow), and left nasal turbinates (white arrow) are shown. Direct examination of sinus aspirate under fluorescence microscopy with calcofluor staining shows broad, ribbonlike hyphae with nondichotomous right-angled branching typical of rhizopus (Panel F). Histopathological analysis of infected tissue with periodic acid–Schiff staining also shows broad, ribbonlike hyphae with nondichotomous right-angled branching (Panel G).

The New England Journal of Medicine is produced by NEJM Group, a division of the Massachusetts Medical Society.
Downloaded from nejm.org by TOM HSIUNG on February 27, 2026.
Copyright © 2026 Massachusetts Medical Society. All rights reserved, including those for text and data mining, AI training, and similar technologies.

Table 2. Laboratory Tools for Diagnosis of Mucormycosis.*

Laboratory Method	Description
Direct examination[45,46]	On direct microscopic examination of a wet mount with potassium hydroxide or fluorescence staining, such as calcofluor or Blankophor, mucorales species typically have ribbonlike, nonseptated (coenocytic) or sparsely septated hyphae that are broad (7 to 15 μm in diameter) with nondichotomous branching. These features help narrow the differential diagnosis by ruling out infection with other pathogenic molds, including *Aspergillus* spp., *Fusarium* spp., and *Scedosporium* spp., which typically appear as slender, dichotomously branching, septated hyphae.
Culture[45-47]	Mucorales species typically grow rapidly to fill the petri dish as a floccose colony on Sabouraud's glucose agar at 25 to 37°C. Recovery of organisms may be enhanced by culturing at 37°C. *Lichtheimia corymbifera* (formerly known as *Absidia corymbifera*) and the most frequently encountered *Rhizopus* spp. and *Mucor* spp. have microscopically distinctive patterns of sporangiophores, sporangia, sporangiospores, and rhizoids (if present). *Cunninghamella* spp. have characteristic denticles and sporangiola instead of sporangiospores.
Antifungal susceptibility testing[48]	Because there are currently no established interpretive breakpoints by which to assess susceptibility, the value of minimum inhibitory concentrations in the management of mucormycosis is limited. Data from in vitro, preclinical animal models and clinical correlation indicate that echinocandins, flucytosine, fluconazole, itraconazole, and voriconazole are not active against mucorales species. Amphotericin B, isavuconazole, and posaconazole are active against the medically important mucorales species in vivo and clinically.
Histopathological analysis[49-51]	Detection of the characteristic ribbonlike, nonseptated or sparsely septate hyphae of the mucorales species in tissue samples with periodic acid–Schiff and Grocott–Gomori methenamine silver stains unequivocally establishes a diagnosis of mucormycosis in the corresponding site. Delays in time to detection may result from formalin fixation, paraffin embedding, sectioning, and staining. Immunohistochemical techniques and fluorescence in situ hybridization further establish a microbiologic diagnosis.
MALDI-TOF MS[52,53]	Recovery of an organism allows rapid molecular identification by MALDI-TOF MS. The informatics database of the MALDI-TOF MS instrument allows clinical laboratories to identify a wide range of medically important mucorales species.
Nucleic acid amplification testing[54-58]	Molecular detection of mucormycosis may be performed with whole blood or BAL fluid. Quantitive PCR assays with primer–probe sets that target the 18S ribosomal RNA have been shown to have the ability to detect *Rhizopus arrhizus*, *Mucor circinelloides*, *L. corymbifera*, and *Cunninghamella bertholletiae* in BAL fluid, plasma, and serum. Nucleic acid amplification assays that are commercially available in Europe, as well as proprietary assays, detect circulating mucorales DNA from BAL fluid, serum, and whole blood. Analysis of cell-free DNA from plasma or serum with the use of a PCR assay offers a new strategy that improves analytical sensitivity over that obtained with traditional whole-blood extractions.
Metagenomic analysis[59,60]	The usefulness of metagenomic analysis of cell-free DNA for the diagnosis of mucormycosis is not well defined. In a recent prospective, multicenter, observational study that involved patients with suspected pneumonia who were immunocompromised and underwent bronchoscopy for evaluation of pneumonic infiltrates of unknown cause, the use of plasma microbial cell-free DNA sequencing significantly increased diagnostic yield as compared with standard-care testing. Among the six fungal pathogens detected only by metagenomic sequencing, two mucorales species were identified.

* BAL denotes bronchoalveolar lavage, MALDI-TOF MS matrix-assisted laser desorption ionization–time-of-flight mass spectrometry, and PCR polymerase chain reaction.

formed when possible. For pleural lesions, a percutaneous needle aspirate may be diagnostic.

Definitive diagnosis of mucormycosis depends on direct examination of clinical specimens, culture of tissue or bronchoalveolar lavage fluid, and histopathological analysis (Table 2). Although availability is limited in many centers, matrix-assisted laser desorption ionization–time-of-flight mass spectrometry, nucleic acid amplification testing, and metagenomic analysis (Table 2) are emerging tools for the early diagnosis of mucormycosis.[45-60]

TREATMENT

The burden of infection, occurrence of dissemination, timeliness of diagnosis, and reversibility of underlying immunodeficiencies are important factors in outcomes and in the assessment of treatment strategies. Successful treatment of mu-

The New England Journal of Medicine is produced by NEJM Group, a division of the Massachusetts Medical Society.
Downloaded from nejm.org by TOM HSIUNG on February 27, 2026.
Copyright © 2026 Massachusetts Medical Society. All rights reserved, including those for text and data mining, AI training, and similar technologies.

cormycosis depends on five pillars of intervention: early detection and staging of the disease, timely initiation of antifungal therapy, surgical resection of infected tissue, reversal of immunodeficiencies, and correction of metabolic abnormalities (Fig. S1 in the Supplementary Appendix, available with the full text of this article at NEJM.org).

ANTIFUNGAL THERAPY

Randomized, controlled trials involving patients with mucormycosis are lacking because of the rarity and tremendous heterogeneity of the disease.[61] Amphotericin B is the primary antifungal agent used for the treatment of mucormycosis.[61] Although prospective, randomized, clinical trials of amphotericin B as compared with placebo are also lacking, the cumulative body of data from animal models, case series, registries, and prospective single-group studies support the use of amphotericin B as primary treatment.[61-65]

LIPID FORMULATIONS OF AMPHOTERICIN B

Liposomal amphotericin B is preferred over amphotericin B deoxycholate because liposomal amphotericin B has less nephrotoxicity than amphotericin B deoxycholate. However, amphotericin B deoxycholate may be the only formulation of amphotericin B available in resource-limited environments. Preclinical and clinical studies of lipid formulations of amphotericin B as compared with amphotericin B deoxycholate have shown that the efficacy of lipid formulations is similar to that of amphotericin B deoxycholate but that lipid formulations have a more favorable safety profile for early treatment of invasive mycoses.[61,66] The most widely used range of doses of liposomal amphotericin B is 5.0 to 7.5 mg per kilogram of body weight per day.[44,61,64] These doses are higher than those typically used for initial treatment of invasive pulmonary aspergillosis (approximately 3 mg per kilogram per day), but they are consistent with doses shown to have efficacy in preclinical models and are compatible with the higher minimum inhibitory concentrations of amphotericin B for mucorales species than for aspergillus. High-dose liposomal amphotericin B (10 mg per kilogram per day) led to a higher risk of nephrotoxic effects than lower doses and was not associated with any apparent improvement in therapeutic outcome.[65] Despite the availability of liposomal amphotericin B, the risk of death from mucormycosis remains unacceptably high among patients with profound immunosuppression,[67] especially in the context of breakthrough infection during treatment with antifungal agents that have activity against mucorales species.[68]

ANTIFUNGAL TRIAZOLES

The only antifungal triazole licensed for primary treatment of mucormycosis is isavuconazole, on the basis of preclinical studies and a single-group, open-label, observational study (Isavuconazole in the Treatment of Renally Impaired Aspergillosis and Rare Fungi [VITAL]).[69] In that study, the responses were compared with those among matched controls from the FungiScope case registry who were treated with liposomal amphotericin B. Isavuconazole is an appropriate alternative to liposomal amphotericin B, especially for extended treatment and for the treatment of patients for whom amphotericin B is not an option because of dose-limiting nephrotoxicity.

In two studies that evaluated the use of posaconazole as salvage therapy, patients received a previous suspension formulation of posaconazole administered in divided doses that totalled 800 mg per day. Among a total of 24 patients with mucormycosis, overall success (defined as a complete or partial response) was 79%.[70] A retrospective study of posaconazole for treatment of refractory mucormycosis in 91 patients showed overall success of 61%.[71] Posaconazole is now administered principally as an extended-release tablet or an intravenous formulation.

COMBINATION THERAPY

Clinical data from studies of combination antifungal therapy are limited.[72,73] A retrospective study that used a propensity-score analysis to evaluate combination therapy for the treatment of mucormycosis in patients with hematologic cancers did not show clinical benefit.[73]

DURATION OF TREATMENT

The duration of treatment of mucormycosis should be individualized for each patient, according to the stage of the infection, response to antifungal therapy, surgical removal of infected tissue, recovery from immune impairment, and the treatment plan for the underlying disease. Therapeutic objectives that define clinical end points of

The New England Journal of Medicine is produced by NEJM Group, a division of the Massachusetts Medical Society.
Downloaded from nejm.org by TOM HSIUNG on February 27, 2026.
Copyright © 2026 Massachusetts Medical Society. All rights reserved, including those for text and data mining, AI training, and similar technologies.

treatment include near normalization of diagnostic imaging, epithelialization of sinus tissue detected on endoscopic examination, and negative follow-up cultures and biopsies of the infected site, as well as recovery from immune impairment. Because relapse of mucormycosis may occur, particularly during periods of repeated cycles of immunosuppression, patients with hematologic cancers who have mucormycosis should receive further long-term secondary prophylaxis with a triazole active against mucorales species, along with careful monitoring if their fungal disease is assessed to be stable.

SURGICAL RESECTION

Surgery has an important role in selected cases. Effective management of mucormycosis calls for multidisciplinary surgical expertise, including that of general, otolaryngologic, ophthalmic, thoracic, orthopedic, and plastic surgeons, depending on the site of infection. Minimally invasive procedures are useful in some patients with limited forms of rhinosinusitis. Complete resection of myocutaneous lesions is indicated to prevent further local extension and hematogenous dissemination. For management of sino-orbital and craniofacial infection, an individual assessment of the extent of disease is indicated. A study in India involving 2826 patients with Covid-19 and sino-orbital-cerebral mucormycosis showed that surgical debridement was beneficial only in early stages of disease.[27] Use of intraoperative staging with specimens processed for fluorescence microscopy or surgical pathological analysis helps to accurately define surgical margins and prevent local recurrence.[74] Because of angioinvasive infarction and the lack of tissue bioavailability of systemic antifungal agents, advanced stages of pulmonary, sino-orbital, cerebral, and myocutaneous mucormycosis are largely surgically treated diseases.

ADJUNCTIVE THERAPEUTICS AND REVERSAL OF UNDERLYING CONDITIONS

Correction of metabolic acidosis and hyperglycemia in patients with diabetes is critical for successful outcomes in cases of sino-orbital or rhinocerebral mucormycosis. Doses of glucocorticoids should be rapidly reduced to the lowest possible effective dose. Recovery from neutropenia is paramount for successful outcomes in mucormycosis. Administration of recombinant human granulocyte colony-stimulating factor or recombinant human GM-CSF shortens the duration of neutropenia and augments phagocytic function. Granulocyte transfusions may be beneficial in stabilizing the disease in selected patients in whom recovery from neutropenia is pending.[75] Hyperbaric oxygen may be beneficial in the management of selected cases of sino-orbital and rhinocerebral mucormycosis in patients with diabetes, as well as cases of isolated myocutaneous mucormycosis.[76,77]

NEW DIRECTIONS FOR IMPROVING OUTCOMES

Variables that influence outcomes in mucormycosis include the stage or location of disease, early diagnosis of invasive disease, timely initiation of antifungal therapy, surgical resection of tissue with medically intractable infection, occurrence of relapsed leukemia, allogeneic hematopoietic-cell transplantation, dissemination of infection, the involvement of the central nervous system, and reversal of immunodeficiencies, which involves remission of underlying hematologic cancers when present.[78] The future research agenda in mucormycosis will be driven by exciting new developments in early diagnosis, new antifungal compounds, virulence targets, and host-directed immune adjunctive therapy (Table 3).[79-93] Laboratory diagnosis of mucormycosis may be improved by expanded availability and use of new culture-independent techniques and tools, including polymerase-chain-reaction analysis of cell-free DNA,[91] metagenomic analysis,[92] new antigen assays, and point-of-care devices, such as loop-mediated isothermal amplification assays.[80]

Augmentation of innate host defenses with multifunctional immunomodulatory agents, including recombinant human GM-CSF, interleukin-7, and other recombinant immunomodulators, may be beneficial in patients with trauma-related immune paralysis and radiation- or chemotherapy-induced neutropenia, contexts in which wound and mucocutaneous healing are important. Small-molecule inhibition of hypoxia-inducible factor 1α, inhibition of epidermal growth factor receptor signaling by gefitinib, and use of inhibitors of programmed death ligand 1 and programmed cell death protein 1 may also be viable therapeutic strategies.[81-83] In addition, adjustment of nasal microbiota may provide defense against colonizing mucorales species.[84]

The New England Journal of Medicine is produced by NEJM Group, a division of the Massachusetts Medical Society.
Downloaded from nejm.org by TOM HSIUNG on February 27, 2026.
Copyright © 2026 Massachusetts Medical Society. All rights reserved, including those for text and data mining, AI training, and similar technologies.

Table 3. Future Directions in Mucormycosis Research.*

Epidemiology	Performance of national and multinational prospective, population-based studies to investigate the incidence of mucormycosis and regional differences in disease Development of multicenter registries of mucormycosis cases to characterize evolving patient-specific risk factors, including diabetes, hematologic cancer, transplantation, trauma, receipt of critical care, and age, as well as outcomes Characterization of immunogenetic risk factors
Laboratory diagnosis	Development of new culture-independent biomarkers with the use of mucorales-specific PCR, cell-free DNA, metagenomics, and volatolomics Further characterization of existing molecular biomarkers for early detection of mucormycosis and correlation of fungal burden with outcome Development of point-of-care diagnostic tools for mucormycosis
Treatment	Development of biomarkers and functional imaging techniques (e.g., PET-CT) for determination of intensity and duration of antifungal therapy Development of new first-in-class antifungal agents Exploration of combination antifungal therapy Harnessing of host-directed immune therapeutics against mucormycosis Development of antivirulence-based therapeutics Elucidation of the effects of metabolic control on risk of mucormycosis and outcomes Characterization of the mechanisms of hyperbaric oxygen therapy and its potential role in treatment of mucormycosis Clarification of the timing and extent of surgery Assessment of the role of local administration (by nebulization or retrobulbar or topical application) of antifungal agents Development of new regulatory pathways and adaptive clinical trials
Outcomes	Definition of the role of diagnostic imaging and biomarkers in outcomes Delineation of the role of coexisting conditions in risk stratification for outcomes Incorporation of patient-reported outcomes into clinical-trial assessments of outcomes Incorporation of desirability-of-outcome ranking into clinical-trial end points

* PET denotes positron-emission tomography.

Several small-molecule antifungal agents have been shown to have in vitro and in vivo activity against mucormycetes and mucormycosis in preclinical studies.[79,85-87] These agents include SCY-247, fosmanogepix, and MAT2203 (an oral nanoparticle amphotericin B formulation). SCY-247, which is a triterpenoid molecule that inhibits synthesis of 1,3-β-D-glucan, has antifungal activity against experimental murine mucormycosis alone and in combination with liposomal amphotericin B. Fosmanogepix is an *N*-phosphonooxymethyl prodrug that is metabolized to the active manogepix molecule, which inhibits Gwt1, the fungal enzyme required for inositol acylation of glycosylphosphatidylinositol anchors.[79] Fosmanogepix has also been shown to have activity in the treatment of experimental murine pulmonary mucormycosis.[85] Similarly, the orally administered lipid nanoparticle MAT2203 has in vivo activity in the neutropenic mouse model of pulmonary mucormycosis.[86] Further investigation of the heritable RNA interference epimutations that result in resistance to antifungal drugs in mucorales species may offer new approaches to understanding the pathogenesis of mucormycosis and combatting the broad antifungal drug resistance of those fungi.[93] As new antineoplastic agents are introduced, complex drug–drug interactions between established and newer antifungal agents will require a personalized approach for each patient.[87]

In cases of mucormycotic wound infection, topical therapy may be beneficial. Dakin's solution (0.025% sodium hypochlorite) is recommended for topical treatment of mucormycotic combat wounds,[88] but therapeutic advances may be possible with new clinically relevant murine models of musculocutaneous mucormycosis and blast injury.[89]

Alternative approaches that target virulence factors of the mucormycetes may also lead to important therapeutic advances. Polyclonal antibodies that target CotH3 proteins protect neutropenic and diabetic ketoacidotic mice from mucormycosis.[90] Polyclonal antibodies against mucoricin prolong survival in mice with experimental mucormycosis.[10]

The future promises to bring combinatorial strategies of early detection in conjunction with

The New England Journal of Medicine is produced by NEJM Group, a division of the Massachusetts Medical Society.
Downloaded from nejm.org by TOM HSIUNG on February 27, 2026.
Copyright © 2026 Massachusetts Medical Society. All rights reserved, including those for text and data mining, AI training, and similar technologies.

KEY POINTS

MUCORMYCOSIS

- Mucormycosis is a rapidly progressive and often lethal invasive fungal infection that affects patients who are severely immunocompromised, as well as patients with diabetes and persons with immunocompetence who have major trauma.
- Mucormycosis manifests in several clinical forms, including sino-orbital, rhinocerebral, sinopulmonary, gastrointestinal, cutaneous, musculoskeletal, osteoarticular, and disseminated mucormycosis, as well as single-organ disease.
- A high index of suspicion in the appropriate clinical context and subsequent microbiologic or histopathological confirmation are necessary for early intervention, which reduces mortality.
- Successful treatment depends on five pillars of intervention: early detection and staging of the disease, timely initiation of antifungal therapy, surgical resection of infected tissue, reversal of immunodeficiencies, and correction of metabolic abnormalities.
- Liposomal amphotericin B is the preferred agent for initial antifungal therapy. Oral triazoles (i.e., isavuconazole and posaconazole) are alternative agents, especially for step-down therapy.
- Research on rapid molecular diagnostic strategies, new antifungal agents, host-directed immune augmentation, antivirulence immune therapeutics, and risk-based stratification to inform management of disease may substantially improve outcomes in patients with this highly destructive mycosis.

the use of antivirulence, antifungal, and immunomodulatory agents, all in concert with efforts to reverse underlying immunodeficiencies and metabolic abnormalities.

Disclosure forms provided by the authors are available with the full text of this article at NEJM.org.

AUTHOR INFORMATION

[1]Department of Infectious Diseases, Infection Control, and Employee Health, University of Texas M.D. Anderson Cancer Center, Houston; [2]Center for Innovative Therapeutics and Diagnostics, Richmond, VA; [3]Department of Medicine, University of Maryland School of Medicine, Baltimore; [4]Department of Microbiology and Immunology, University of Maryland School of Medicine, Baltimore.

REFERENCES

1. Kwon-Chung KJ. Taxonomy of fungi causing mucormycosis and entomophthoramycosis (zygomycosis) and nomenclature of the disease: molecular mycologic perspectives. Clin Infect Dis 2012; 54:Suppl 1:S8-S15.
2. Roden MM, Zaoutis TE, Buchanan WL, et al. Epidemiology and outcome of zygomycosis: a review of 929 reported cases. Clin Infect Dis 2005;41:634-53.
3. Walsh TJ, Hospenthal DR, Petraitis V, Kontoyiannis DP. Necrotizing mucormycosis of wounds following combat injuries, natural disasters, burns, and other trauma. J Fungi (Basel) 2019;5:57.
4. Özbek L, Topçu U, Manay M, et al. COVID-19–associated mucormycosis: a systematic review and meta-analysis of 958 cases. Clin Microbiol Infect 2023;29:722-31.
5. Muthu V, Agarwal R, Rudramurthy SM, et al. Risk factors, mortality, and predictors of survival in COVID-19-associated pulmonary mucormycosis: a multicentre retrospective study from India. Clin Microbiol Infect 2024;30:368-74.
6. Cheok KPL, Farrow A, Springell D, et al. Mucormycosis after CD19 chimeric antigen receptor T-cell therapy: results of a US Food and Drug Administration adverse events reporting system analysis and a review of the literature. Lancet Infect Dis 2024;24(4):e256-e265.
7. Anastasopoulou A, DiPippo AJ, Kontoyiannis DP. Non-Aspergillus invasive mould infections in patients treated with ibrutinib. Mycoses 2020;63:787-93.
8. WHO fungal priority pathogens list to guide research, development and public health action. Geneva: World Health Organization, 2022 (https://iris.who.int/server/api/core/bitstreams/69af4379-4f27-4ac4-8973-74d7b52af7bd/content).
9. Ma L-J, Ibrahim AS, Skory C, et al. Genomic analysis of the basal lineage fungus *Rhizopus oryzae* reveals a whole-genome duplication. PLoS Genet 2009;5(7):e1000549.
10. Soliman SSM, Baldin C, Gu Y, et al. Mucoricin is a ricin-like toxin that is critical for the pathogenesis of mucormycosis. Nat Microbiol 2021;6:313-26.
11. Chakrabarti A, Singh R. Mucormycosis in India: unique features. Mycoses 2014;57:Suppl 3:85-90.
12. Seidel D, Wurster S, Jenks JD, et al. Impact of climate change and natural disasters on fungal infections. Lancet Microbe 2024;5(6):e594-e605.
13. Gomes MZR, Lewis RE, Kontoyiannis DP. Mucormycosis caused by unusual mucormycetes, non-Rhizopus, -Mucor, and -Lichtheimia species. Clin Microbiol Rev 2011;24:411-45.
14. Petraitis V, Petraitiene R, Antachopoulos C, et al. Increased virulence of *Cunninghamella bertholletiae* in experimental pulmonary mucormycosis: correlation with circulating molecular biomarkers, sporangiospore germination and hyphal metabolism. Med Mycol 2013;51:72-82.
15. Gebremariam T, Liu M, Luo G, et al. CotH3 mediates fungal invasion of host cells during mucormycosis. J Clin Invest 2014;124:237-50.
16. Lockhart SR, Bialek R, Kibbler CC, Cuenca-Estrella M, Jensen HE, Kontoyiannis DP. Molecular techniques for genus and species determination of fungi from fresh and paraffin-embedded formalin-fixed tissue in the revised EORTC/MSGERC definitions of invasive fungal infection. Clin Infect Dis 2021;72:Suppl 2:S109-S113.
17. Lax C, Nicolás FE, Navarro E, Garre V. Molecular mechanisms that govern infection and antifungal resistance in Mucorales. Microbiol Mol Biol Rev 2024;88(1): e0018822.
18. Andrianaki AM, Kyrmizi I, Thanopoulou K, et al. Iron restriction inside macrophages regulates pulmonary host defense against Rhizopus species. Nat Commun 2018;9:3333.
19. Alqarihi A, Kontoyiannis DP, Ibrahim AS. Mucormycosis in 2023: an update on pathogenesis and management. Front Cell Infect Microbiol 2023;13:1254919.
20. Pikoulas A, Morianos I, Nidris V, et al.

The New England Journal of Medicine is produced by NEJM Group, a division of the Massachusetts Medical Society.
Downloaded from nejm.org by TOM HSIUNG on February 27, 2026.
Copyright © 2026 Massachusetts Medical Society. All rights reserved, including those for text and data mining, AI training, and similar technologies.

Albumin orchestrates a natural host defence mechanism against mucormycosis. Nature 2026;649:693-702.
21. Alqarihi A, Gebremariam T, Gu Y, et al. GRP78 and integrins play different roles in host cell invasion during mucormycosis. mBio 2020;11(3):e01087-20.
22. Hoffman T, Haviv Y, Cohen A, et al. Invasive mould infections following combat-related injuries — a retrospective cohort study. Mycoses 2025;68(2):e70028.
23. Rees JR, Pinner RW, Hajjeh RA, Brandt ME, Reingold AL. The epidemiological features of invasive mycotic infections in the San Francisco Bay area, 1992-1993: results of population-based laboratory active surveillance. Clin Infect Dis 1998;27:1138-47.
24. Kontoyiannis DP, Yang H, Song J, et al. Prevalence, clinical and economic burden of mucormycosis-related hospitalizations in the United States: a retrospective study. BMC Infect Dis 2016;16:730.
25. Kontoyiannis DP, Marr KA, Park BJ, et al. Prospective surveillance for invasive fungal infections in hematopoietic stem cell transplant recipients, 2001-2006: overview of the Transplant-Associated Infection Surveillance Network (TRANSNET) database. Clin Infect Dis 2010;50:1091-100.
26. Gamaletsou MN, Sipsas NV, Roilides E, Walsh TJ. Rhino-orbital-cerebral mucormycosis. Curr Infect Dis Rep 2012;14:423-34.
27. Sen M, Honavar SG, Bansal R, et al. Epidemiology, clinical profile, management, and outcome of COVID-19-associated rhino-orbital-cerebral mucormycosis in 2826 patients in India — collaborative OPAI-IJO study on mucormycosis in COVID-19 (COSMIC), report 1. Indian J Ophthalmol 2021;69:1670-92.
28. Pyrgos V, Shoham S, Walsh TJ. Pulmonary zygomycosis. Semin Respir Crit Care Med 2008;29:111-20.
29. Ben-Ami R, Luna M, Lewis RE, Walsh TJ, Kontoyiannis DP. A clinicopathological study of pulmonary mucormycosis in cancer patients: extensive angioinvasion but limited inflammatory response. J Infect 2009;59:134-8.
30. Godoy MCB, Viswanathan C, Marchiori E, et al. The reversed halo sign: update and differential diagnosis. Br J Radiol 2012;85:1226-35.
31. Bourcier J, Heudes P-M, Morio F, et al. Prevalence of the reversed halo sign in neutropenic patients compared with non-neutropenic patients: data from a single-centre study involving 27 patients with pulmonary mucormycosis (2003-2016). Mycoses 2017;60:526-33.
32. Tribble DR, Ganesan A, Rodriguez CJ. Combat trauma-related invasive fungal wound infections. Curr Fungal Infect Rep 2020;14:186-96.
33. Taj-Aldeen SJ, Gamaletsou MN, Rammaert B, et al. Bone and joint infections caused by mucormycetes: a challenging osteoarticular mycosis of the twenty-first century. Med Mycol 2017;55:691-704.
34. Sundermann AJ, Clancy CJ, Pasculle AW, et al. Remediation of mucorales-contaminated healthcare linens at a laundry facility following an investigation of a case cluster of hospital-acquired mucormycosis. Clin Infect Dis 2022;74:1401-7.
35. Lee SC, Billmyre RB, Li A, et al. Analysis of a food-borne fungal pathogen outbreak: virulence and genome of a Mucor circinelloides isolate from yogurt. mBio 2014;5(4):e01390-14.
36. Oliver MR, Van Voorhis WC, Boeckh M, Mattson D, Bowden RA. Hepatic mucormycosis in a bone marrow transplant recipient who ingested naturopathic medicine. Clin Infect Dis 1996;22:521-4.
37. Roilides E, Zaoutis TE, Katragkou A, Benjamin DK Jr, Walsh TJ. Zygomycosis in neonates: an uncommon but life-threatening infection. Am J Perinatol 2009;26:565-73.
38. Chikley A, Ben-Ami R, Kontoyiannis DP. Mucormycosis of the central nervous system. J Fungi (Basel) 2019;5:59.
39. Pappas PG, Alexander BD, Andes DR, et al. Invasive fungal infections among organ transplant recipients: results of the Transplant-Associated Infection Surveillance Network (TRANSNET). Clin Infect Dis 2010;50:1101-11.
40. Zaoutis TE, Roilides E, Chiou CC, et al. Zygomycosis in children: a systematic review and analysis of reported cases. Pediatr Infect Dis J 2007;26:723-7.
41. Corzo-León DE, Chora-Hernández LD, Rodríguez-Zulueta AP, Walsh TJ. Diabetes mellitus as the major risk factor for mucormycosis in Mexico: epidemiology, diagnosis, and outcomes of reported cases. Med Mycol 2018;56:29-43.
42. Chowdhary A, Gupta N, Wurster S, et al. Multimodal analysis of the COVID-19-associated mucormycosis outbreak in Delhi, India indicates the convergence of clinical and environmental risk factors. Mycoses 2023;66:515-26.
43. Walther G, Wagner L, Kurzai O. Outbreaks of mucorales and the species involved. Mycopathologia 2020;185:765-81.
44. Chamilos G, Lewis RE, Kontoyiannis DP. Delaying amphotericin B-based frontline therapy significantly increases mortality among patients with hematologic malignancy who have zygomycosis. Clin Infect Dis 2008;47:503-9.
45. Walsh TJ, Gamaletsou MN, McGinnis MR, Hayden RT, Kontoyiannis DP. Early clinical and laboratory diagnosis of invasive pulmonary, extrapulmonary, and disseminated mucormycosis (zygomycosis). Clin Infect Dis 2012;54:Suppl 1:S55-60.
46. Lackner N, Posch W, Lass-Flörl C. Microbiological and molecular diagnosis of mucormycosis: from old to new. Microorganisms 2021;9:1518.
47. Kontoyiannis DP, Chamilos G, Hassan SA, Lewis RE, Albert ND, Tarrand JJ. Increased culture recovery of Zygomycetes under physiologic temperature conditions. Am J Clin Pathol 2007;127:208-12.
48. Badali H, Cañete-Gibas C, McCarthy D, et al. Epidemiology and antifungal susceptibilities of mucoralean fungi in clinical samples from the United States. J Clin Microbiol 2021;59(9):e0123021.
49. Spallone A, Moran CA, Wurster S, Axell-House DB, Kontoyiannis DP. Taking a closer look: clinical and histopathological characteristics of culture-positive versus culture-negative pulmonary mucormycosis. J Fungi (Basel) 2022;8:380.
50. Schuetz AN, Walsh TJ. Importance of fungal histopathology in immunocompromised pediatric patients: it's not just "*Aspergillus*" anymore. Am J Clin Pathol 2015;144:185-7.
51. Jung J, Park YS, Sung H, et al. Using immunohistochemistry to assess the accuracy of histomorphologic diagnosis of aspergillosis and mucormycosis. Clin Infect Dis 2015;61:1664-70.
52. Walsh TJ, McCarthy MW. The expanding use of matrix-assisted laser desorption/ionization-time of flight mass spectroscopy in the diagnosis of patients with mycotic diseases. Expert Rev Mol Diagn 2019;19:241-8.
53. Fissel JA, Holdren-Serrell CK, Memon W, Zhang SX. Performance of a matrix-assisted laser desorption/ionization time-of-flight mass spectrometry testing algorithm for the rapid identification of clinical filamentous molds. Front Cell Infect Microbiol 2022;12:915049.
54. Kasai M, Harrington SM, Francesconi A, et al. Detection of a molecular biomarker for zygomycetes by quantitative PCR assays of plasma, bronchoalveolar lavage, and lung tissue in a rabbit model of experimental pulmonary zygomycosis. J Clin Microbiol 2008;46:3690-702.
55. Hammond SP, Bialek R, Milner DA, Petschnigg EM, Baden LR, Marty FM. Molecular methods to improve diagnosis and identification of mucormycosis. J Clin Microbiol 2011;49:2151-3.
56. Millon L, Caillot D, Berceanu A, et al. Evaluation of serum Mucorales polymerase chain reaction (PCR) for the diagnosis of mucormycoses: the MODIMUCOR prospective trial. Clin Infect Dis 2022;75:777-85.
57. Guegan H, Iriart X, Bougnoux ME, Berry A, Robert-Gangneux F, Gangneux JP. Evaluation of MucorGenius mucorales PCR assay for the diagnosis of pulmonary mucormycosis. J Infect 2020;81:311-7.
58. Imbert S, Portejoie L, Pfister E, et al. A multiplex PCR and DNA-sequencing workflow on serum for the diagnosis and species identification for invasive aspergillosis and mucormycosis. J Clin Microbiol 2023;61(1):e0140922.
59. Hogan CA, Yang S, Garner OB, et al. Clinical impact of metagenomic next-generation sequencing of plasma cell-free

The New England Journal of Medicine is produced by NEJM Group, a division of the Massachusetts Medical Society.
Downloaded from nejm.org by TOM HSIUNG on February 27, 2026.
Copyright © 2026 Massachusetts Medical Society. All rights reserved, including those for text and data mining, AI training, and similar technologies.

DNA for the diagnosis of infectious diseases: a multicenter retrospective cohort study. Clin Infect Dis 2021;72:239-45.
60. Bergin SP, Chemaly RF, Dadwal SS, et al. Plasma microbial cell-free DNA sequencing in immunocompromised patients with pneumonia: a prospective observational study. Clin Infect Dis 2024;78:775-84.
61. Cornely OA, Alastruey-Izquierdo A, Arenz D, et al. Global guideline for the diagnosis and management of mucormycosis: an initiative of the European Confederation of Medical Mycology in cooperation with the Mycoses Study Group Education and Research Consortium. Lancet Infect Dis 2019;19(12):e405-e421.
62. Ibrahim AS, Avanessian V, Spellberg B, Edwards JE Jr. Liposomal amphotericin B, and not amphotericin B deoxycholate, improves survival of diabetic mice infected with Rhizopus oryzae. Antimicrob Agents Chemother 2003;47:3343-4.
63. Luo G, Gebremariam T, Lee H, et al. Efficacy of liposomal amphotericin B and posaconazole in intratracheal models of murine mucormycosis. Antimicrob Agents Chemother 2013;57:3340-7.
64. Shoham S, Magill SS, Merz WG, et al. Primary treatment of zygomycosis with liposomal amphotericin B: analysis of 28 cases. Med Mycol 2010;48:511-7.
65. Lanternier F, Poiree S, Elie C, et al. Prospective pilot study of high-dose (10 mg/kg/day) liposomal amphotericin B (L-AMB) for the initial treatment of mucormycosis. J Antimicrob Chemother 2015;70:3116-23.
66. Walsh TJ, Finberg RW, Arndt C, et al. Liposomal amphotericin B for empirical therapy in patients with persistent fever and neutropenia. N Engl J Med 1999;340:764-71.
67. Hammond SP, Baden LR, Marty FM. Mortality in hematologic malignancy and hematopoietic stem cell transplant patients with mucormycosis, 2001 to 2009. Antimicrob Agents Chemother 2011;55:5018-21.
68. Axell-House DB, Wurster S, Jiang Y, et al. Breakthrough mucormycosis developing on mucorales-active antifungals portrays a poor prognosis in patients with hematologic cancer. J Fungi (Basel) 2021;7:217.
69. Marty FM, Ostrosky-Zeichner L, Cornely OA, et al. Isavuconazole treatment for mucormycosis: a single-arm open-label trial and case-control analysis. Lancet Infect Dis 2016;16:828-37.
70. Greenberg RN, Mullane K, van Burik J-AH, et al. Posaconazole as salvage therapy for zygomycosis. Antimicrob Agents Chemother 2006;50:126-33.
71. van Burik J-AH, Hare RS, Solomon HF, Corrado ML, Kontoyiannis DP. Posaconazole is effective as salvage therapy in zygomycosis: a retrospective summary of 91 cases. Clin Infect Dis 2006;42(7):e61-e65.
72. Reed C, Bryant R, Ibrahim AS, et al. Combination polyene-caspofungin treatment of rhino-orbital-cerebral mucormycosis. Clin Infect Dis 2008;47:364-71.
73. Kyvernitakis A, Torres HA, Jiang Y, Chamilos G, Lewis RE, Kontoyiannis DP. Initial use of combination treatment does not impact survival of 106 patients with haematologic malignancies and mucormycosis: a propensity score analysis. Clin Microbiol Infect 2016;22(9):811.e1-811.e8.
74. McDermott NE, Barrett J, Hipp J, et al. Successful treatment of periodontal mucormycosis: report of a case and literature review. Oral Surg Oral Med Oral Pathol Oral Radiol Endod 2010;109(3):e64-e69.
75. Quillen K, Wong E, Scheinberg P, et al. Granulocyte transfusions in severe aplastic anemia: an eleven-year experience. Haematologica 2009;94:1661-8.
76. Ferguson BJ, Mitchell TG, Moon R, Camporesi EM, Farmer J. Adjunctive hyperbaric oxygen for treatment of rhinocerebral mucormycosis. Rev Infect Dis 1988;10:551-9.
77. Pandey S, Kumar V, Kumar R, Mishra B, Singh A, Reddy G. Effectiveness of hyperbaric oxygen therapy in the management of COVID-19-associated mucormycosis. Med Gas Res 2024;14:87-8.
78. Dailey Garnes NJM, Kontoyiannis DP. Mucormycosis: update on clinical presentation, diagnosis, and treatment. Curr Opin Infect Dis 2023;36:427-35.
79. Hoenigl M, Arastehfar A, Arendrup MC, et al. Novel antifungals and treatment approaches to tackle resistance and improve outcomes of invasive fungal disease. Clin Microbiol Rev 2024;37(2):e0007423.
80. Roy R, Singh G, Dahiya UR, Pandey M, Xess I, Kalyanasundaram D. Rapid detection of Mucorales in human blood and urine samples by functionalized Heusler magnetic nanoparticle assisted customized loop-mediated isothermal amplification. Med Mycol 2024;62:myae007.
81. Kavaliauskas P, Gu Y, Hasin N, et al. Multiple roles for hypoxia inducible factor 1-alpha in airway epithelial cells during mucormycosis. Nat Commun 2024;15:5282.
82. Watkins TN, Gebremariam T, Swidergall M, et al. Inhibition of EGFR signaling protects from mucormycosis. mBio 2018;9(4):e01384-18.
83. Wurster S, Albert ND, Bharadwaj U, et al. Blockade of the PD-1/PD-L1 immune checkpoint pathway improves infection outcomes and enhances fungicidal host defense in a murine model of invasive pulmonary mucormycosis. Front Immunol 2022;13:838344.
84. Singh R, Kumari A. Nasal microbiota imbalance as a contributory link in the emergence of COVID-19 associated mucormycosis. ACS Infect Dis 2021;7:2211-3.
85. Gebremariam T, Alkhazraji S, Alqarihi A, et al. Fosmanogepix (APX001) is effective in the treatment of pulmonary murine mucormycosis due to *Rhizopus arrhizus*. Antimicrob Agents Chemother 2020;64(6):e00178-20.
86. Gu Y, Gebremariam T, Alkhazraji S, et al. Efficacy of an oral lipid nanocrystal formulation of amphotericin B (MAT2203) in the neutropenic mouse model of pulmonary mucormycosis. Antimicrob Agents Chemother 2024;68(6):e0154023.
87. Douglas AP, Lamoth F, John TM, et al. American Society of Transplantation and Cellular Therapy series: #8 — management and prevention of non-Aspergillus molds in hematopoietic cell transplantation recipients. Transplant Cell Ther 2025;31:194-223.
88. Joint Trauma System Clinical Practice Guideline (JTS CPG): invasive fungal infection in war wounds. July 17, 2023 (https://jts.health.mil/assets/docs/cpgs/Invasive_Fungal_Infection_in_War_Wounds_17_Jul_2023_ID28.pdf).
89. Samdavid Thanapaul RJR, Alamneh YA, Finnegan DK, et al. Development of a combat-relevant murine model of wound mucormycosis: a platform for the preclinical investigation of novel therapeutics for wound-invasive fungal diseases. J Fungi (Basel) 2024;10:364.
90. Gebremariam T, Alkhazraji S, Soliman SSM, et al. Anti-CotH3 antibodies protect mice from mucormycosis by prevention of invasion and augmenting opsonophagocytosis. Sci Adv 2019;5(6):eaaw1327.
91. Faure E, Cordier C, Delacoste H, et al. Weekly screening of circulating mucorales DNA and early treatment in severely burned patients improves survival: real-life bi-center experience in France. Clin Infect Dis 2025;81:907-13.
92. Sim BZ, Mah JK, Heldman MR, et al. Plasma microbial cell-free DNA metagenomic sequencing for diagnosis of invasive fungal diseases among high-risk outpatient and inpatient immunocompromised hosts. Clin Infect Dis 2025;81:1008-14.
93. Pérez-Arques C, Navarro-Mendoza MI, Xu Z, Walther G, Heitman J. RNAi epimutations conferring antifungal drug resistance are inheritable. Nat Commun 2025;16:7293.

Copyright © 2026 Massachusetts Medical Society.

The New England Journal of Medicine is produced by NEJM Group, a division of the Massachusetts Medical Society.
Downloaded from nejm.org by TOM HSIUNG on February 27, 2026.
Copyright © 2026 Massachusetts Medical Society. All rights reserved, including those for text and data mining, AI training, and similar technologies.